

# Hereditary Transthyretin-Mediated Amyloidosis (hATTR) Clinical Clues and Diagnostic Testing Quick Reference Guide

- Transthyretin-mediated amyloidosis (ATTR) is a form of systemic amyloidosis caused by amyloid deposits in tissues and organs derived from TTR (transthyretin) protein, primarily produced in the liver.<sup>1</sup>
- ATTR amyloidosis can be acquired or inherited. Wild-type ATTR (wATTR) amyloidosis presents primarily with cardiac manifestations, whereas hereditary or variant ATTR (hATTR or ATTRv) amyloidosis variably involves the heart and autonomic and peripheral nerves. Inheritance for hATTR amyloidosis is autosomal dominant with variable penetrance.<sup>2</sup>
- Perceived rarity of the disease and clinical manifestations similar to other more common diseases like heart failure can lead to delays in the identification and diagnosis of ATTR amyloidosis. The list of clinical clues and diagnostic testing provided in this quick reference guide are intended to promote earlier identification and accurate diagnosis of ATTR amyloidosis, with subsequent genetic testing to determine if there is a genetic cause. Confirmation of a TTR variant should trigger genetic counseling and potential screening for family members.<sup>3</sup>

## Clinical Clues<sup>3,4,5</sup>

### Traditional Cardiac Clues

Intolerance to antihypertensive or heart failure medications because of symptomatic hypotension or orthostasis

Persistent low-level elevation in serum troponin

Discordance between QRS voltage on an ECG and wall thickness on imaging

Unexplained atrioventricular block or prior pacemaker implantation

Unexplained LV wall thickening, right ventricular thickening, or atrial wall thickening

Family history of cardiomyopathy

**Abbreviations:** LV, left ventricular

### Noncardiac Clues

Neurological: sensorimotor polyneuropathy (paresthesias and weakness), autonomic dysfunction (orthostatic hypotension, postprandial diarrhea alternating with constipation, gastroparesis, urinary retention, and incontinence)

Orthopedic: carpal tunnel syndrome, lumbar spinal stenosis, unprovoked biceps tendon rupture, hip and knee arthroplasty

Black race

Family history of polyneuropathy

Adapted with permission from Kittleson et al.<sup>3</sup> Copyright 2020 American Heart Association, Inc.

## References

<sup>1</sup> UK National Amyloidosis Centre. Amyloidosis Patient Information Site. <http://www.amyloidosis.org.uk/about-amyloidosis/hereditary-systemic-amyloidosis/introduction-to-attr-amyloidosis>. Published July 13, 2020. Accessed December 7, 2021.

<sup>2</sup> Patel KS, Hawkins PN. Cardiac amyloidosis: Where are we today? *Journal of Internal Medicine*. 2015;278(2):126-144. doi:10.1111/joim.12383

<sup>3</sup> Kittleson MM, Maurer MS, Ambardekar AV, Bullock-Palmer RP, Chang PP, Eisen HJ, Nair AP, Nativi-Nicolau J, Ruberg FL; on behalf of the American Heart Association Heart Failure and Transplantation Committee of the Council on Clinical Cardiology. Cardiac amyloidosis: evolving diagnosis and management: a scientific statement from the American Heart Association. *Circulation*. 2020;142:e7-e22. doi: 10.1161/CIR.0000000000000792.

<sup>4</sup> Witteles RM, Bokhari S, Damy T, et al. Screening for transthyretin amyloid cardiomyopathy in everyday practice. *JACC: Heart Failure*. 2019;7(8):709-716. doi:10.1016/j.jchf.2019.04.010

<sup>5</sup> Ruberg FL, Maurer MS, Judge DP, et al. Prospective evaluation of the morbidity and mortality of wild-type and v122i mutant transthyretin amyloid cardiomyopathy: The Transthyretin Amyloidosis Cardiac Study (TRACS). *American Heart Journal*. 2012;164(2). doi:10.1016/j.ahj.2012.04.015

<sup>6</sup> Adams D, Ando Y, Melo Beirao J, et al. Expert consensus recommendations to improve diagnosis of ATTR amyloidosis with polyneuropathy. *Journal of Neurology*. 2021;268(6):2109-2122. doi: 10.1007/s00415-019-09688-0

## Diagnostic Testing for Suspected hATTR Amyloidosis with Cardiomyopathy<sup>3</sup>

### Abbreviations:

ECG electrocardiogram

HCM hypertrophic cardiomyopathy

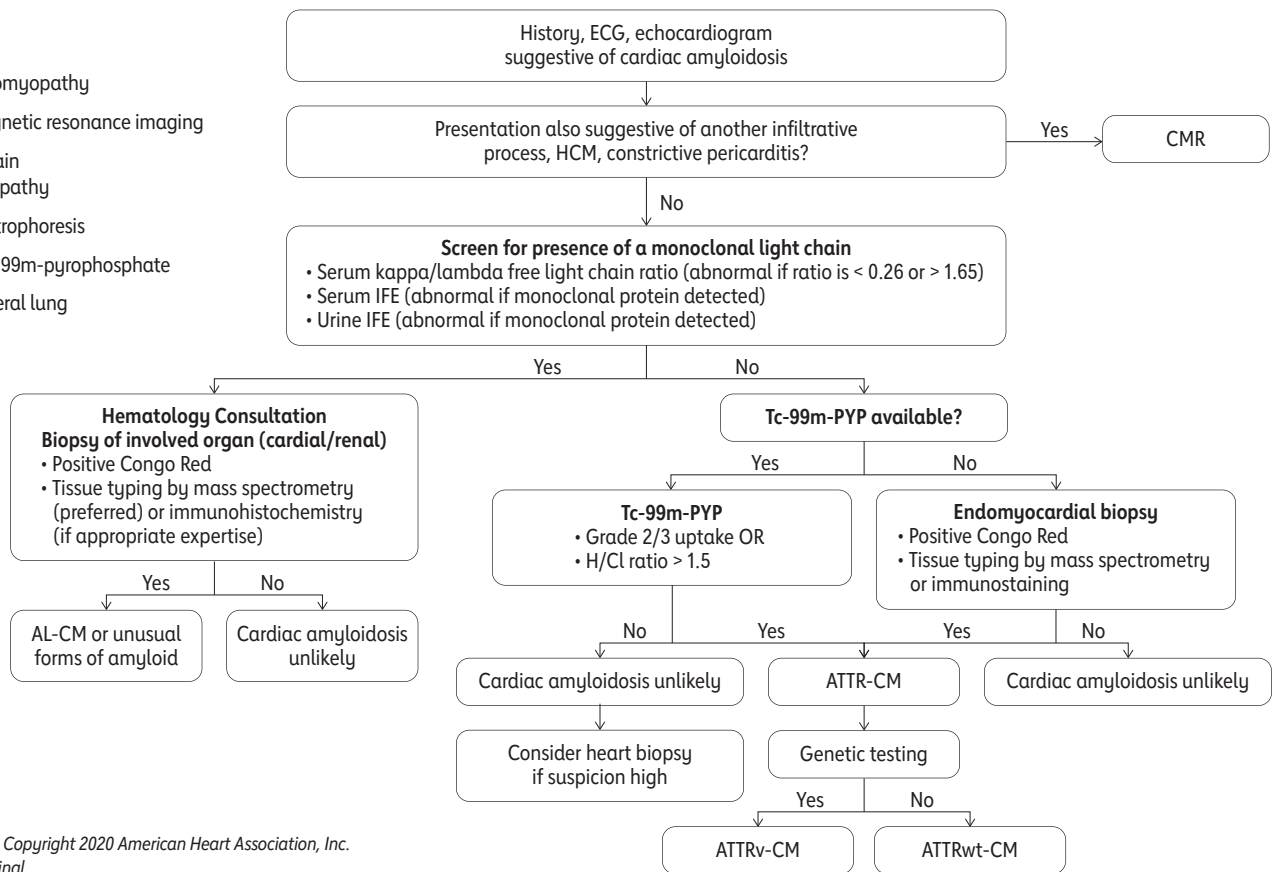
CMR cardiovascular magnetic resonance imaging

AL-CM amyloid light-chain amyloidosis cardiomyopathy

IFE immunofixation electrophoresis

Tc-99m-PYP technetium-99m-pyrophosphate

H/CL heart-to-contralateral lung



Adapted from Kittleson et al.<sup>3</sup> Copyright 2020 American Heart Association, Inc. Formatting changes from original.

## Diagnostic Testing for Suspected hATTR Amyloidosis with Polyneuropathy<sup>6</sup>

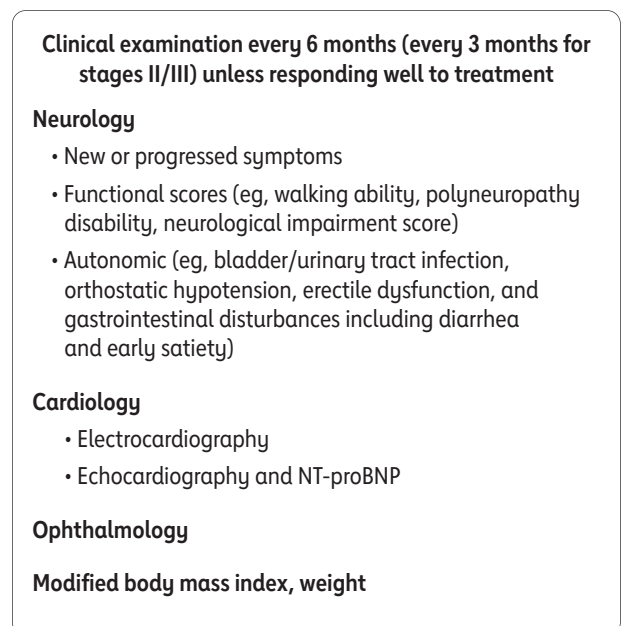
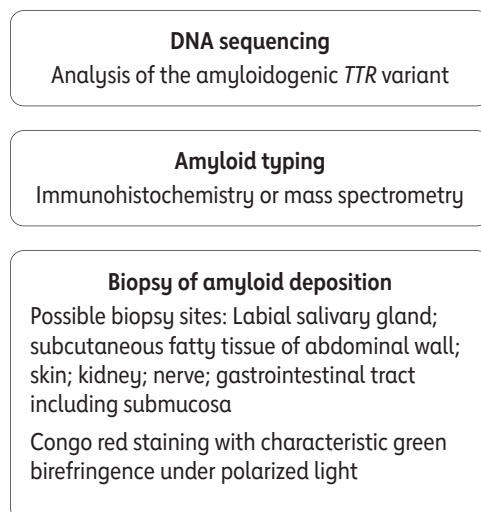
Clinical suspicion of amyloid neuropathy



Confirmation of ATTRv amyloidosis



Patient follow-up after diagnosis



### Abbreviations:

NT-proBNP N-terminal pro-brain natriuretic peptide

Adapted from Adams et al.<sup>6</sup> Copyright 2020 The Authors. Formatting changes from original.