

Medically Challenging Cases: Severe postoperative ARDS in the lung cancer patient  
Elise Sullivan MD, Ameeka Pannu MD, Shahzad Shaefi MD, Brian O'Gara MD  
Beth Israel Deaconess Medical Center, Boston, MA

Case Presentation:

JL is a 73M with a 15+ pack year smoking history who presented for lobectomy for stage IIIA lung adenocarcinoma. After neoadjuvant chemoradiation, JL underwent a left upper lobectomy via thoracotomy. Notably, intraoperative pulmonary artery injury resulted in total blood loss of 2.5 liters.

Post-operatively, the patient was transferred to the surgical ICU. He was extubated on post-operative day 3, but required re-intubation and cardioversion for ventricular tachycardia. Over the next 24 hours, the patient developed severe respiratory failure. CTA of the chest demonstrated moderate pulmonary edema and multifocal consolidations predominantly on the right side (see Figure 1). His PaO<sub>2</sub>/FiO<sub>2</sub> ratio was 58, signifying severe ARDS. Potential etiologies for this occurrence included aspiration pneumonitis and retraction injury. He was started on ARDSnet ventilation settings, inhaled pulmonary vasodilator therapy, and was chemically paralyzed.<sup>1</sup> Despite these efforts, the patient's condition continued to deteriorate.

After consideration of the patient's mortality risk, inadequacy of rescue therapy, and confirmation of preserved cardiac function, the decision was made to institute veno-venous extracorporeal membrane oxygenation (VV ECMO) through a dual staged jugular venous cannula. Over the course of the next 4 days, the patient exhibited improved oxygenation, ventilation and organ perfusion. His cannula was removed on POD 9. After decannulation, fibroproliferative ARDS resulted in persistent difficulties with maintaining adequate oxygenation. However, after a prolonged weaning period and tracheostomy, he was discharged to long term ventilator rehabilitation on post-operative day 43.

Discussion:

This case highlights the ongoing discussion of appropriate application of ECMO therapy. In deciding whether a patient is a viable candidate for ECMO, numerous factors must be taken into account. Proposed exclusion criteria include elevated peak inspiratory pressures, high FiO<sub>2</sub> for more than 7 days, intracranial bleeding, contraindication to heparinization or to continuation of active treatment.<sup>2</sup> Its use comes at significant financial and physical cost, with multiple risks including hemorrhage, thrombosis and thromboembolism, gas embolism, infection, and vessel injury.<sup>3</sup> Therefore, judicious and selective use of this invasive therapy is imperative. Data have shown at least one significant complication occurs in greater than 50% of all patients on ECMO.<sup>4</sup>

JL's history of cancer, risk of bleeding from his recent operation, pulmonary artery injury, and age were concerning risk factors which argued against the use of ECMO. His mortality was determined to be greater than 50% at the time of cannulation. In contrast, JL's estimated 60% estimated 5 year survival from an oncologic standpoint argued that he

could recover to a reasonable quality of life. Ultimately, the use of VV ECMO was life-saving without the occurrence of a debilitating complication, but it is unclear whether he will be able to regain independent functional status. After his extended ICU course, JL was discharged to long term rehabilitation in close proximity to his wife, three children and multiple grandchildren. He requires significant physical rehabilitation but is neurologically intact. His case therefore demonstrates 'successful' use of ECMO but the long term morbidity of this technology is currently understudied.

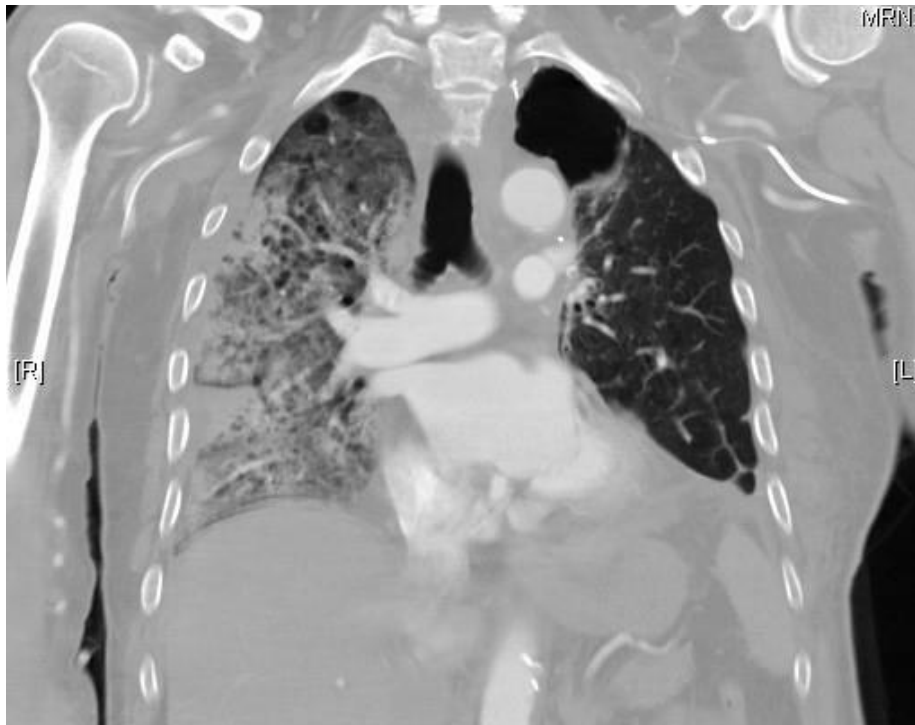


Figure 1: Coronal section of CTA chest showing extensive patchy consolidation, right worse than left. Also noted is the absence of the left upper lobe.

<sup>1</sup> The Acute Respiratory Distress Syndrome Network. Ventilation with lower tidal volumes as compared with traditional tidal volumes for acute lung injury and the acute respiratory distress syndrome. *N Engl J Med* 2000; 342: 1301–08.

<sup>2</sup> Peek GJ, Mugford M, Tiruvoipati R et al. Efficacy and economic assessment of conventional ventilatory support versus extracorporeal membrane oxygenation for severe adult respiratory failure (CESAR): a multicentre randomised controlled trial. *Lancet* 2009; 374: 1351–63

<sup>3</sup> US FDA ECMO Executive Summary. Classification of the Membrane Lung for Long-term Pulmonary Support.

<sup>4</sup> Combes A, Leprince P, Luyt CE, Bonnet N, Trouillet JL, Leger P, et al. Outcomes and long-term quality-of-life of patients supported by extracorporeal membrane oxygenation for refractory cardiogenic shock. *Crit Care Med.* 2008;36(5):1404–11.